



Guided Endodontic Micro-Surgery (GEMS): A Novel Approach for a Targeted Apicoectomy—A Report of 3 Cases

Hamid R. Abedi^{1,2} Farzad Foroughi^{3,4} Muaz Zendaki⁵

¹ Department of Endodontics, Cornerstone Dental Specialties, Inc, Irvine, United States

² Department of Endodontics, School of Dentistry, Loma Linda University, Loma Linda, California, United States

³ Department of Research and Development, Cornerstone Specialty Products LLC., Irvine, United States

⁴ Department of Endodontics, School of Dentistry, University of California Los Angeles (UCLA), Los Angeles, United States

⁵ Department of Restorative Dentistry CERT, University of California Los Angeles (UCLA), Los Angeles, United States

Address for correspondence Farzad Foroughi, PhD, School of Dentistry, University of California Los Angeles (UCLA), 9950 Irvine Centre Drive, Irvine, CA 92618, United States (e-mail: fforoughi@cspdental.com).

Dent J Adv Stud 2022;10:161–169.

Abstract

Guided endodontic microsurgery, also known as guided endodontic microsurgery, is a surgical procedure used to treat failed endodontically treated teeth with periapical infections. Guided endodontic microsurgery can be problematic in some situations, such as when there are tough anatomical features or limited surgical access. Some of these complex cases can be managed using cone beam computed tomography imaging, CAD software design, and 3D printing technologies. A surgical stent was manufactured using a 3D printer in each of the three cases. Prior to surgery, the infection location, depth, and angulation of preparation were determined to protect sensitive anatomical components. The target location is chosen to ensure precise root excision and avoid infection during surgery. Infected root tip resection and biopsy were accomplished in one step by rotating a trephine bur in the surgical stent hole. Once the root preparation and the retrograde filling were completed, bone graft material can be added to the surgical site and then the tissues were sutured to achieve primary closure. Surgical stents produce effective targeted apicoectomy with a certain angle and depth of preparation. In addition, the soft tissue is reflected or protected with the unique features of the stent.

Keywords

- ▶ guided endodontic microsurgery
- ▶ apical surgery
- ▶ surgical stent
- ▶ apicectomy
- ▶ 3D printing

Introduction

There have been significant advances in endodontic surgery over the past two decades; gone are the antiquated and

mechanistic procedures to be replaced with biological approaches, newer materials aided by improved lighting and magnification and microsurgical techniques. Apical surgery expanded and is now often known as “apical

article published online
November 8, 2022

DOI <https://doi.org/10.1055/s-0042-1758227>.
ISSN 2321-1482.

© 2022. Bhojia Dental College and Hospital affiliated to Himachal Pradesh University. All rights reserved.

This is an open access article published by Thieme under the terms of the Creative Commons Attribution-NonDerivative-NonCommercial-License, permitting copying and reproduction so long as the original work is given appropriate credit. Contents may not be used for commercial purposes, or adapted, remixed, transformed or built upon. (<https://creativecommons.org/licenses/by-nc-nd/4.0/>)

Thieme Medical and Scientific Publishers Pvt. Ltd., A-12, 2nd Floor, Sector 2, Noida-201301 UP, India

microsurgery.” These advances helped to improve the outcome of endodontic surgery, which was previously considered a rather unpredictable procedure. Microsurgical techniques with new root filling materials reported a favorable healing outcome of 88 at 96%.¹⁻⁴

Guided endodontic microsurgery (GEMS) is a technique that can potentially simplify the surgery. Through the use of cone beam computed tomography (CBCT), CAD software design and three-dimensional (3D) printing technology, it was possible to address these three difficult cases. Some research articles and presentations in this field explain the use of a unique hard-tissue drill guide derived from implant surgery.⁵ There are currently limited comprehensive techniques that address both hard and soft tissues in a flapless surgery. The authors have developed a soft-tissue guide integrated with the hard-tissue guide. This will enable minimally traumatic surgery on the patient for both hard and soft tissues. The authors have performed more than 30 surgeries using the GEMS procedure and are now working on studies with the University of California, San Francisco. In addition, exciting work is being done to allow for guided retrograde filling. The GEMS protocol was written by the Research and Development team at Cornerstone Specialty Products. The protocol allows the doctor to follow the instructions step by step to correctly integrate the GEM. First, the doctor must perform a full CBCT and intraoral scan of the patient. The intraoral IO scan must sufficiently cover enough buccal soft tissue up to the mucobuccal fold, many IO scanners allow operators to disable artificial intelligence (A. I.) scan to extend beyond the limits of the attached gingiva. After completion, the final step is the doctor will send the .*dicom* and .*stl* file formats to the design studio.

Dental surgical stents can be used to help dentists perform apicoectomies with confidence and ease. A hard tissue stent will have an access hole formed on one side and supported by the occlusal surface of one or more of the patient's teeth with the access hole precisely aligned in a location for drilling to remove an infection. For example, a hard tissue stent would be placed over one or more of the patient's teeth, and the stent would contain a marker that is placed where the surgeon needs to cut to create an access flap in the soft tissue. The tab attached to the semi-circular window of the hard tissue stent makes it easier for the surgeon to return the tab to the correct position.⁶

The purpose of this study was to offer a novel GEMS approach for tissue reflection and guided endodontic surgery that uses an accurate surgical method.

Materials and Methods

A 100 × 80 mm preoperative CBCT scan was required (Veraview ×800; J Morita USA, Inc., Irvine, CA) and their image was saved in the *dicom* file format (► Fig. 1A) and the patients were scanned by an intraoral scanner (iTero element; Align Technology, Phoenix, AZ) (► Fig. 1B). Then, both files were merged in the Implant Studio Software (3Shape Inc., Warren, NJ) for the design of a surgical stent. Once that was completed, the surgical guide was made by 3D printer (Formlabs, Somerville,

MA). The diameter of the trephine bur, the depth of penetration, and the site of periapical infection were determined using CBCT and 3D scanner information and the Osseoset 200 low-speed motor (Nobel Biocare, Yorba Linda, CA) was used to deliver safe treatments through its high-performance drilling and precise torque control. All study participants provided and signed an informed consent form.

The important part of GEMS is the flap design which will result in proper access and optimized postoperative healing. The basic principles of flap design should be followed. ► Fig. 1A, shows the different soft tissue separators based on the different flap designs. According to the root anatomy, the flaps can be designed vertically, full flap envelope or semi Lunar. One of the problems in using surgical stents after soft tissue incision is that the tissue because it is soft, causes be in the path and thus causes the tissue to disintegrate, so a tissue separator is designed for the surgical stent, which can keep the tissue stable during surgery. The stopper should be put on the trephine tip before using the trephine bur and the stopper pressed against the stent hole to limit penetration depth (► Fig. 1A, 1E). There are different sizes for the trephine bur that are recommended sizes for each tooth you are treating. In an electric surgical handpiece (Osseoset 200) with sterile water irrigation, a 4- or 5-mm outer-diameter trephine bur was rotated at 1000 to 1200 rpm with 35 to 50 Ncm torque, gradually cutting through the bone, root end, and soft tissue with a slow pecking motion over 30 seconds depending on the depth of cutting. The trephine was taken from the bone and the root end was removed after cutting. To eliminate soft and hard tissue debris, bleeding, blood clots, and extra root-end filling material, the surgical site is flushed with sufficient volumes of sterile saline. Root-end filling using Endosequence BC Root Repair Material (Brasseler USA, Savannah, GA) or Endo-Eze MTA Flow (Ultradent, South Jordan, UT) was performed under a surgical operating microscope (SEILER Alpha Air 6 Step, Saint Louis, MO) (Ultradent, South Jordan, UT).⁶ For medication, antibiotics (500 mg amoxicillin caps thrice per day for 7 days), Analgesics (400 mg dexibuprofen, thrice per day for 5 days) and rinsing with chlorhexidine gluconate (0.12%, 15 mL twice per day) were prescribed to all cases for 5 days. There were no postoperative complications, and the healing process was normal.

Case Report

Case 1: Maxillary Left Second Premolar Palatal Root

A 57-year-old woman patient was referred to the Cornerstone Training Institute (CTI), Irvine, California with sporadic discomfort, swelling, and tenderness to percussion in the left maxillary region of teeth #13. Three-dimensional digital panoramic and intraoral X-rays revealed radiolucency indicating per-apical lesion of tooth #13 (► Fig. 2).

To extract the end of the palatal root from the facial cortex with an inclusion depth of 11 mm, a drill bit with an outer diameter of 4 mm is needed at the angulation. The flap was kept by tissue separator and the surgical stent was inserted. The trephine bur was placed in the stent and apical surgery

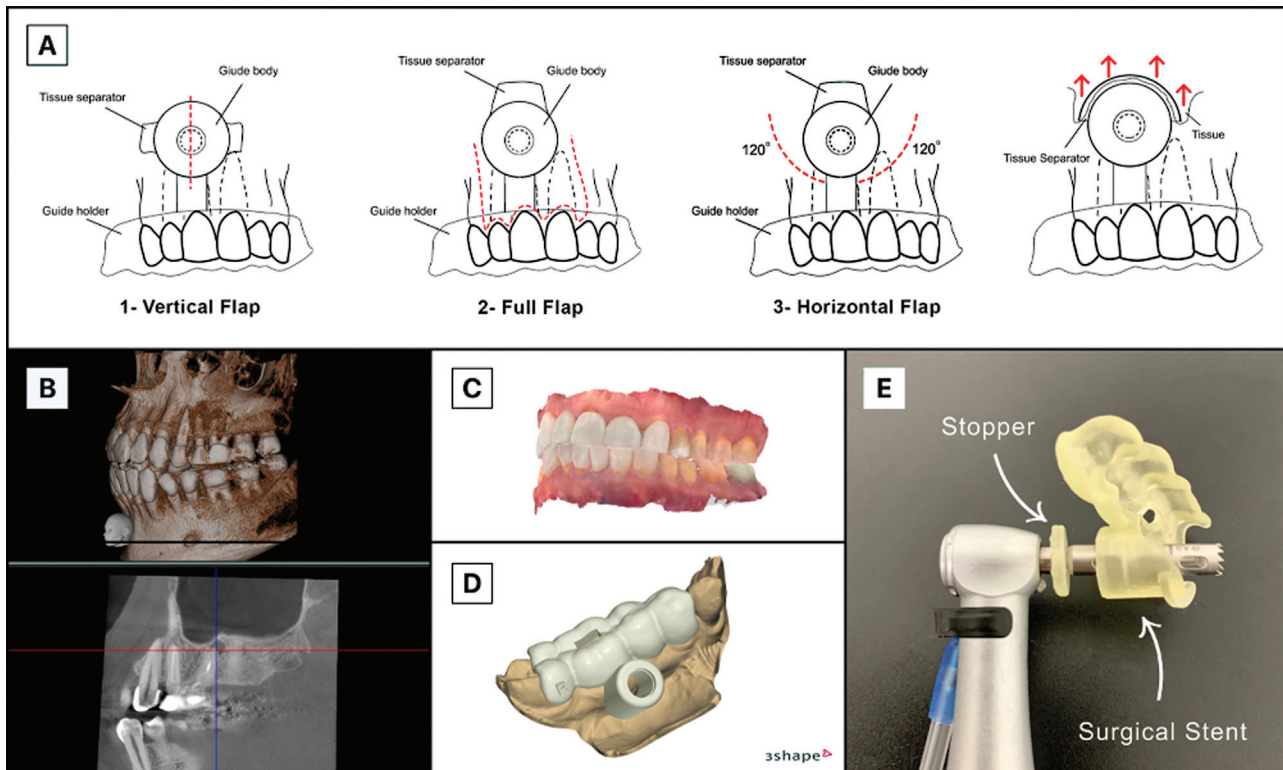


Fig. 1 Targeted GEMS Overview. It needs two digital files for designing the stent. The doctor uploads both files on the Laboratory Studio Design webpage. (A) Illustration of different flaps (Vertical (a1), Full flap (a2) and Horizontal (a3)), (b) CBCT sagittal view of the infection (.dicom format). (C) 3D intra oral scan (.stl format), (D) exported both format files to 3Shape software and design a customize stent for the patient. (E) After designing the stent is sent to the 3D printer (Form 2, FormLabs, Somerville, MA).

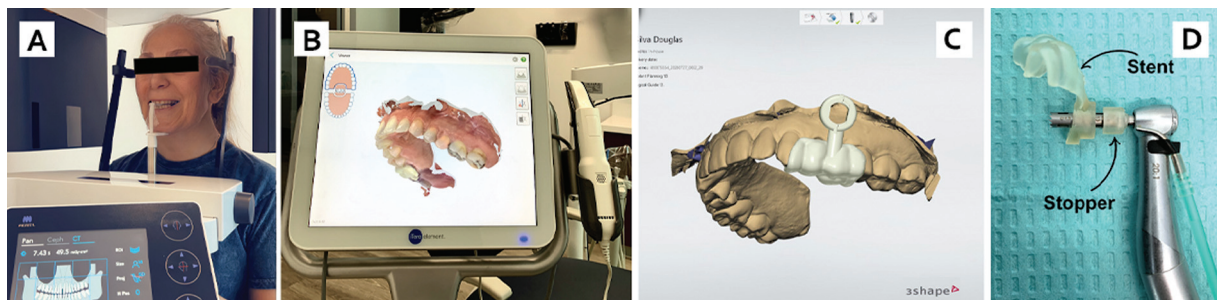


Fig. 2 Tooth #13. (A) Take a CBCT from the patient, (B) The process of Intraoral scanning, (C) Design the surgical guide by Implant Studio software and (D) Trephine bur placed in the surgical stent with 3D-printed stopper for depth control.

was performed. The gutta-percha was burnished and OsteoGen Plug (Impladent Ltd., Jamaica, NY) was placed in the socket and sutured with 5-0 Vicryl (Ethicon US LLC, Cincinnati, OH). The patient after 1 week and 1 month was asymptomatic. At the 5-month follow-up, the patient was clinically asymptomatic with no sensitivity to percussion and no bleeding on probing, and probing depths at all sites of tooth #13 was < 3 mm (►Fig. 5).

Case 2: Lateral Incisor

A 46-year-old male patient was referred to CTI with sporadic discomfort, swelling, and tenderness to percussion in the left maxillary region of tooth #10. The tooth had retreated previously. The patient was chosen for targeted endodontic surgery after CBCT imaging indicated a low-

density region at the tip of tooth #10. A 3D scan was acquired with a CBCT system and intraoral scanner, and the resulted digital files were united at the design studio software. The trephine bur was placed in the stent and osteotomy was performed. The gutta percha was burnished and OsteoGen Plug (Impladent Ltd., Jamaica, NY) was placed in the socket and the site was closed with 5-0 Vicryls. At the 5-month follow-up, the patient was clinically asymptomatic with no sensitivity to percussion and no bleeding on probing, and probing depths at all sites of tooth #10 was < 3 mm (►Fig. 3 and ►Fig. 6).

Case 3: Maxillary right First Molar MB root

A 63-year-old man presented with pain in the maxillary right posterior tooth. At the apex of tooth #3, CBCT

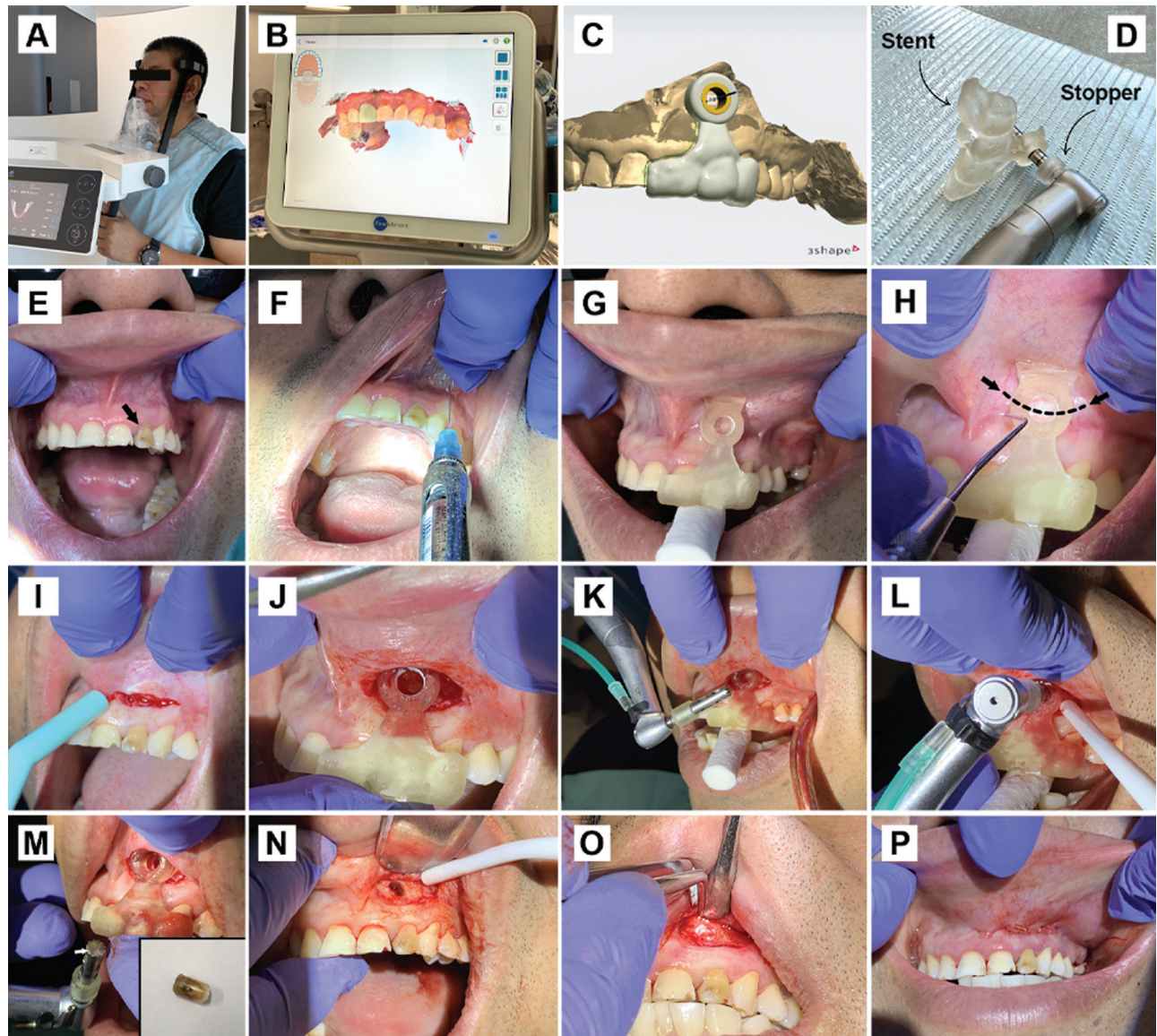


Fig. 3 Tooth #10. (A) Take a CBCT from the patient, (B) The process of Intraoral scanning, (C) Design the surgical guide by Implant Studio software, (D) Trephine bur placed in surgical stent with 3D-printed stopper for depth control, (E) Tooth #10 marked with a black arrow, (F) lidocaine 2% 1:100k epi, (G-I) Flap design: A properly designed, and carefully reflected flap will result in proper access and post-op healing, (J) The stent should be placed gently on the teeth so that the tissue is directed toward the back of the tissue separator, (K) After putting the surgical stent on the patient's teeth, the patient should bite the surgical stent and keep it for stability. They can also bite on a bite block, (L) Practice caution and move slowly while drilling through bone until the stopper touches the stent body. The Stopper is designed according to the working length, (M, N) Bone and root tip are removed. Usually, the hard tissue is stuck inside the trephine bur, (O) Bone graft material is mixed with sterile saline and applied to the surgical site until the hole is filled, (P) 5–0 chromic gut suture is used which is resorbable.

imaging revealed a low-density area measuring 100×80 mm. CBCT imaging revealed a low-density area of the apex of tooth #10 and the patient elected to have a targeted surgical stent. A 3D scan was designed with a CBCT system and intraoral scanner to accommodate a 4 mm OD trephine in the angulation required to extract the fused end of the mesiobuccal root from the facial cortex with an insertion depth of 15 mm. A surgical stent and stopper were designed with the trephine bur in a position that would prevent infection to the maxillary sinus. GEMS was performed (–Fig. 4). The trephine bur was placed in the stent and osteotomy was performed. Root end preparation was performed with piezoelectric

ultrasonics and filled with MTA root repair material. The place was closed with 4–0 Vicryl.

At the 4-month follow-up, the patient was clinically asymptomatic with no sensitivity to percussion and no bleeding on probing, and probing depths at all sites of tooth #3 was < 3 mm (–Fig. 7C).

Results and Discussion

GEMS can be used in treating anatomically complex scenarios including lesions close to the nerve, the maxillary sinus and arteries.^{7,8} Studies show deviations in 22% of cases using traditional apicoectomy compared with the

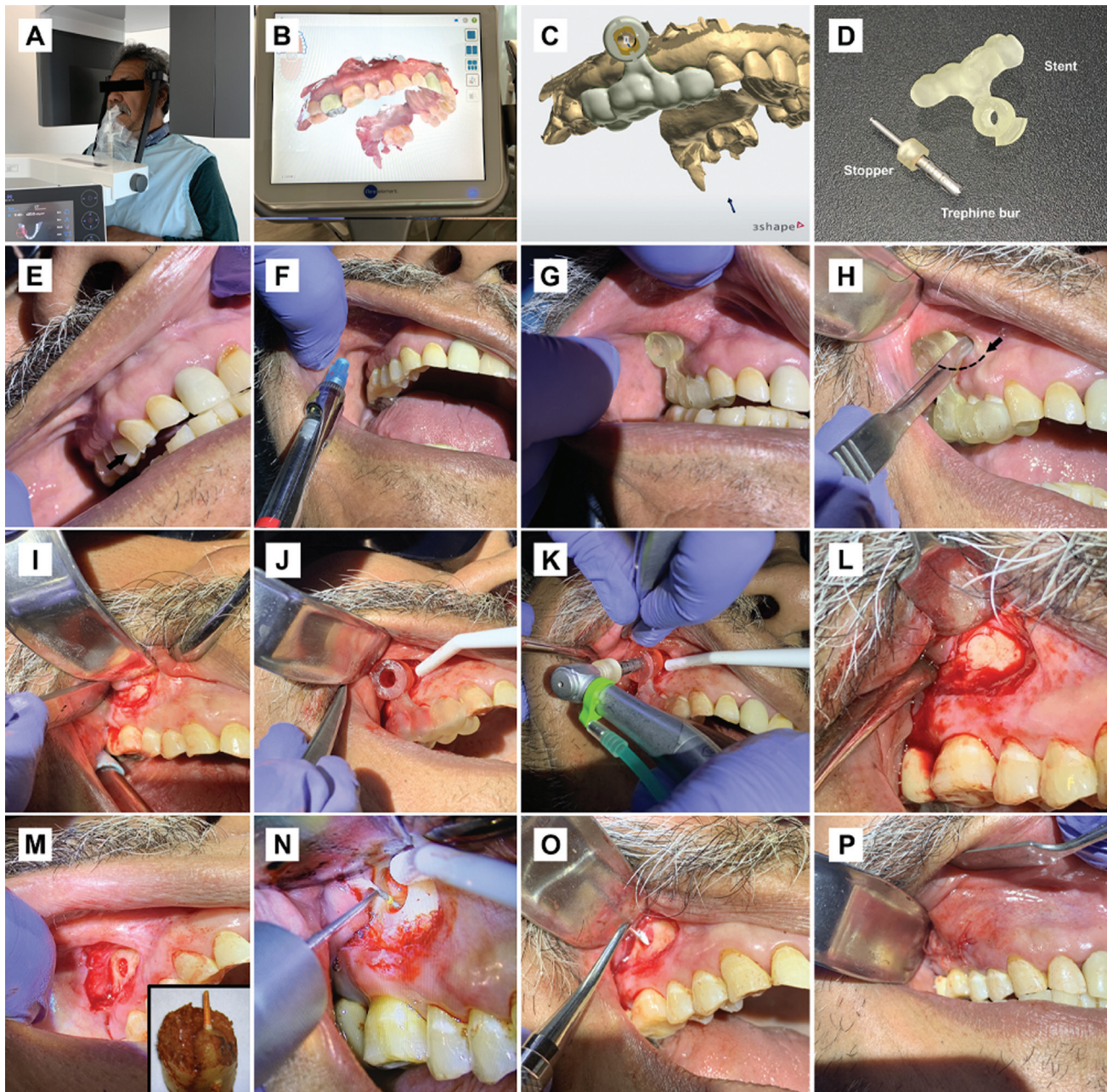


Fig. 4 Tooth #3. (A) Take a CBCT from the patient, (B) The process of Intraoral scanning, (C) Design the surgical guide by Implant Studio software, (D) Trephine bur placed into stent with 3D-printed stopper for depth control, (E) Tooth #10 marked with a black arrow, (F) Using lidocaine 2% with epinephrine 1:100,000 has been shown to give long-lasting anesthesia, (G-I) Flap design: A properly designed, and carefully reflected flap will result in proper access and post-op healing, (J) The stent should be placed gently on the teeth so that the tissue is directed toward the back of the tissue separator, (K) After putting the surgical stent on the patient's teeth, the patient should bite the surgical stent and keep it for stability. They can also bite on a bite block, (I) Practice caution and move slowly while drilling through bone until the stopper touches the stent body. The stopper is designed according to the working length, (M, N) Bone and root tip are removed. Usually, the hard tissue is stuck inside the trephine bur, (O) Bone graft material is mixed with sterile saline and applied to the surgical site until the hole is filled, (P) 5-0 chromic gut suture is used which is absorbable.

precision of guided apicoectomy.⁹ In case 1, The surgical stent allowed an osteotomy depth of 11 mm for the operation of the root treatment. The simplification of surgical steps through GEMS can increase dentists' confidence in having safer and more conservative surgical approach. In case 2 The maxillary sinus was preserved due to the precision of the guiding surgery via GEMS method. The use of tailored GEMS to simplify the surgical

processes most likely will increase the clinical prevalence of apical surgeries in general and increase the rate of saving teeth versus extraction.

The ongoing refinement of the surgical stent applications, it is possible to create minimally invasive surgical treatments that are customized for each patient. GEMS also open the door for improving retrograde root filling utilizing MTA based sealers and also allows the utilization of the

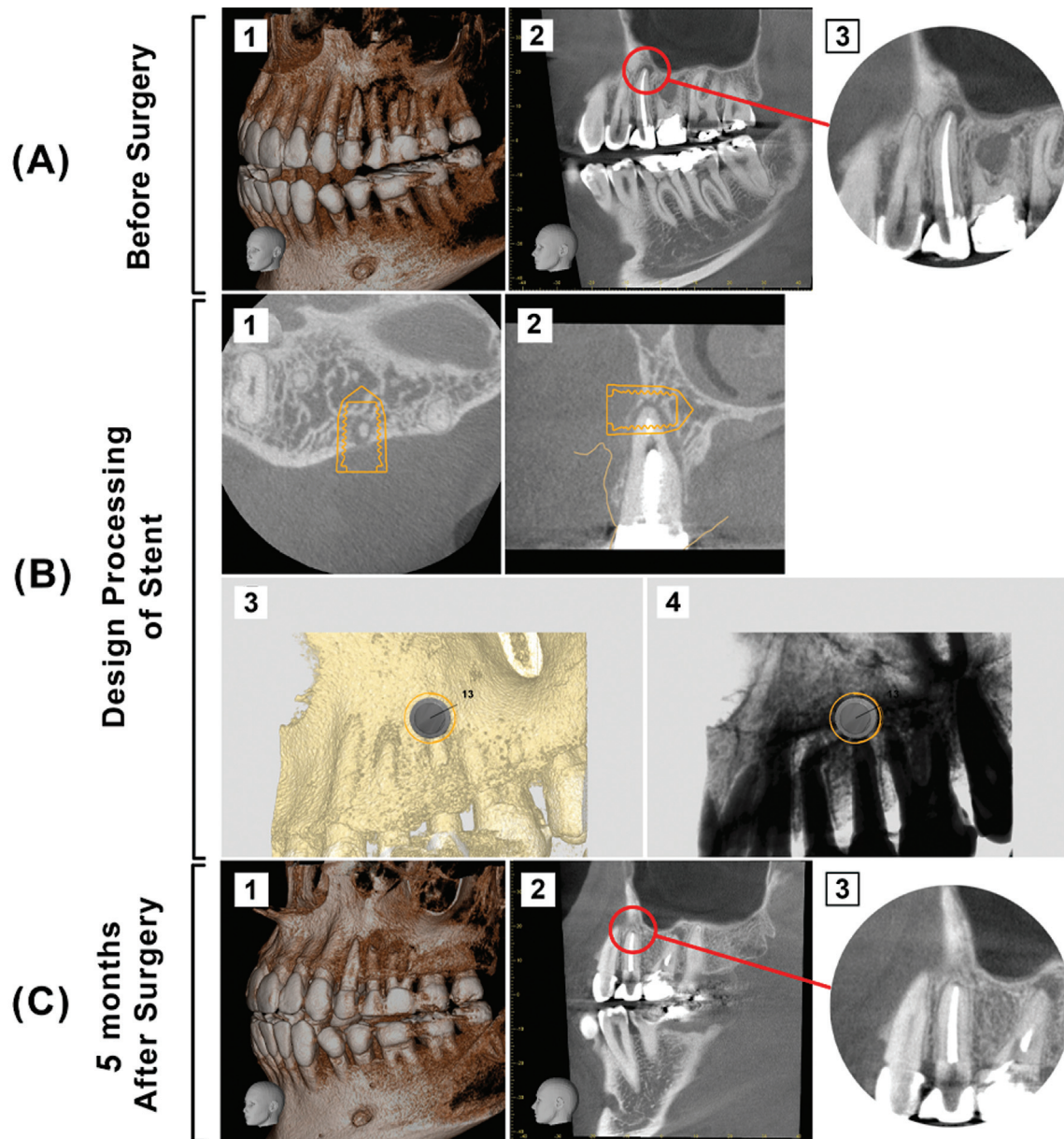


Fig. 5 Case 1. (A) As you show, tooth #13 has a large infection, (B) According to the CBCT and intraoral scanner file, the designer team, designed a customized stent by 3Shape software, (C) Follow-up the patient after 5 months. C-3, the bone has healed, and the patient is asymptomatic.

autogenous bone excised around the root tip as possible addition to the bone graft to be used in the surgical site.

Generally, guided apicoectomy has the potential to be a more accurate and conservative apical surgery that can in most of the cases replace the more invasive traditional apicoectomy. Another potential advantage of guided surgery stent is to help with tissue retraction and protection. Once the flap is fixed by tissue separators, the stent will function as a safeguard as well, minimizing trauma to soft tissue. In addition, a stopper is attached to trephine bur that helps to measure the working area from the beginning of stent hole to the extent of the lesion or infected area (► Fig. 5).

Limiting factors need to be considered before using GEMS method. This is a procedure that requires advanced dental solutions such as the need of CBCT imaging, specialized

dental software for digital designs and 3D printing capacity.¹⁰

To mitigate the cost of expensive 3D printer the accuracy of inexpensive benchtop 3D printers for guided endodontic surgery is being evaluated.

Furthermore, clinicians must understand the importance of accurate measurements to assure adequate fit and design of the surgical stent in relation to the GEMS protocol, to avoid heat injury to bone, and preserve surrounding soft tissue and sensitive anatomical structures before performing GEMS.

Long-term GEMS patient-centered outcome studies are needed (► Figs. 6 and 7).

Another exciting similar application in the world of guided endodontics is the process of endodontic 3D template technique for the preparation of orthograde access cavities

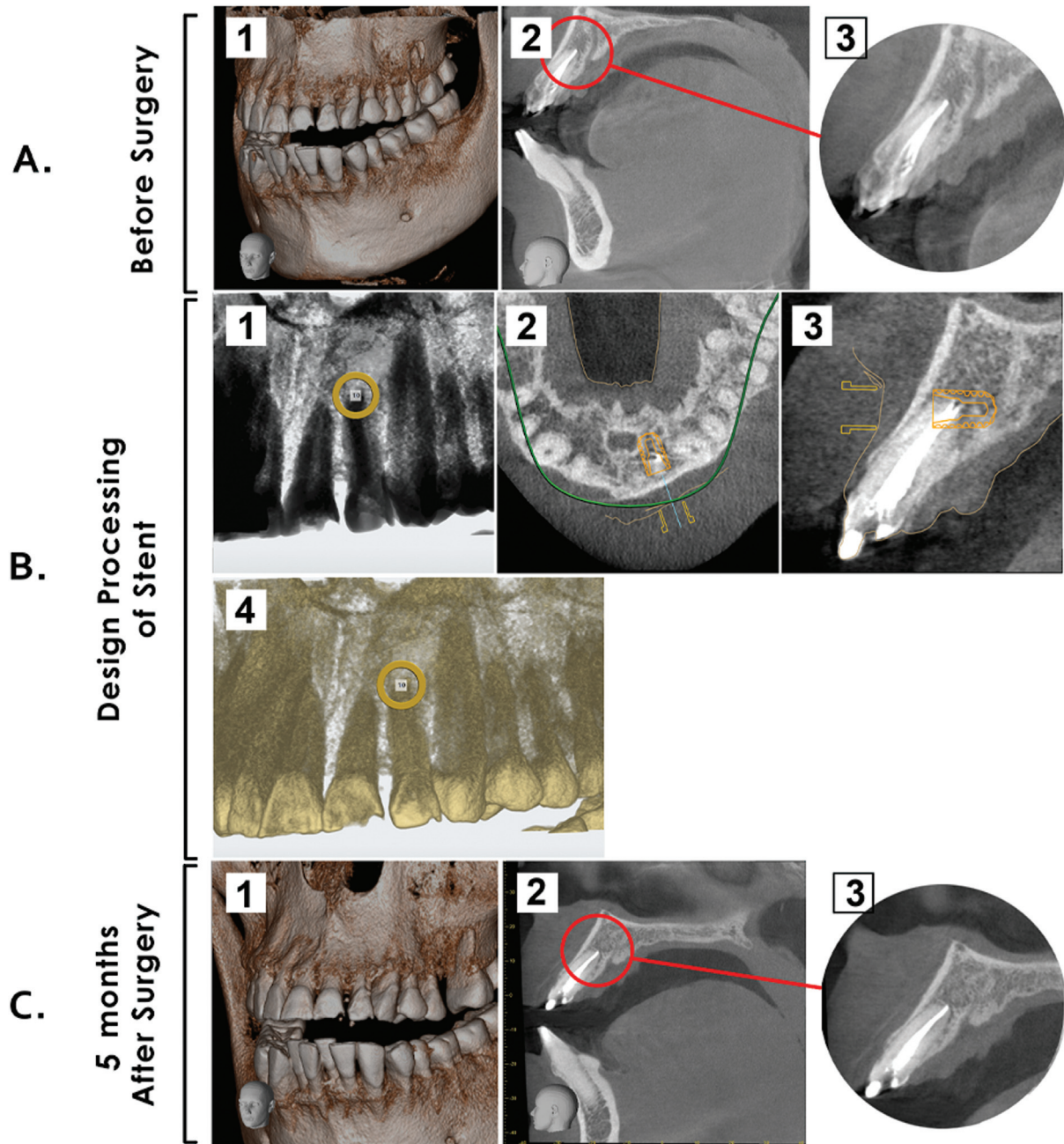


Fig. 6 Case 2. (A) As you show, tooth #10 has a big infection, (B) According to the CBCT and intraoral scanner file, the designer team, designed a customized stent by 3Shape software, (C) Follow-up the patient after 5 months. As you see in picture C-3, the bone has good healing, and the patient doesn't have any issues and pain.

and the cleaning and shaping of root canals, with the limitation that the technique can only be used for anterior teeth; however, the results are promising.^{11,12}

In contrast to guided root canal treatment our surgical approach was able to show that 3D printed templates can be used for the treatment of single or multiple roots with anterior or posterior locations as radiographic, dicom and optical scan files are merged into a single surgical template.

The diameter of the bony defect is inversely related to the success rate endodontic surgeries and may result in delayed

healing after apicoectomies,^{13,14} this may also result in post-operative complications. A surgical lesion that is not fully removed, including infections, initiates the inflammatory process that causes postoperative issues such as swelling and pain.¹⁵ Reducing the extent of the infection can help reduce post-surgical issues. Therefore, a guided apical surgery with a 3D printed surgical stent can reduce post-surgical issues as it provides a more accurate understanding of the true extent of the lesion preoperatively and improves the chances for full excision and curettage using the access created by the surgical stent during the surgery.

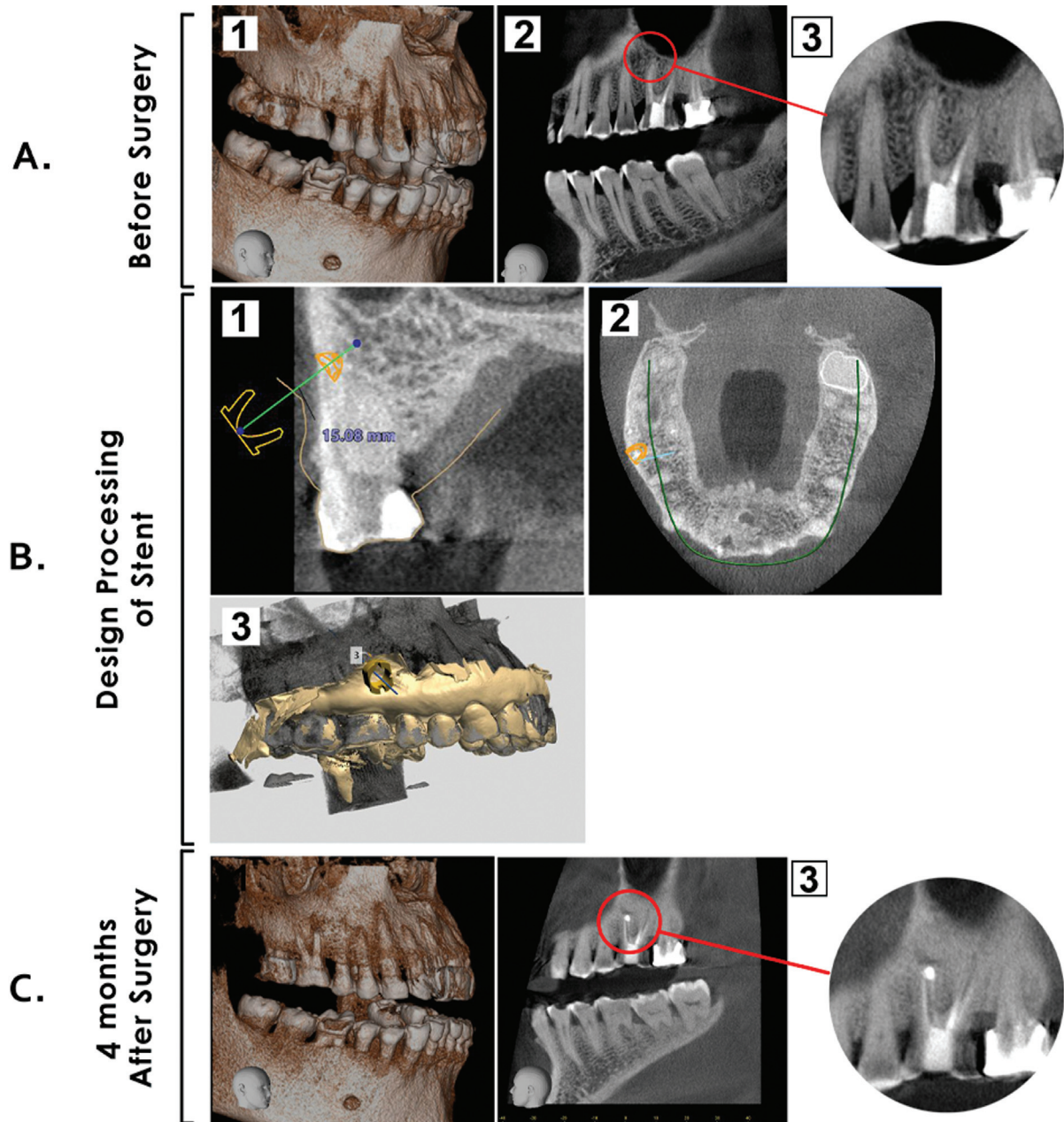


Fig. 7 Case 3. (A) As shown, tooth #3 has a large infection, (B) According to the CBCT and intraoral scanner file, the designer team, designed a customized stent by 3Shape software, (C) Followed up with the patient after 4 months. As you see in picture C-3, the bone has healed, and the patient doesn't have any issues or pain.

3D surgical stent offers highly accurate apical surgery that is customizable to each patient. Depending on the specified surgical location, the personally designed surgical guide may be supported through the mucosa, teeth and bone.^{11,12,16,18} In the prevailing case report, osteotomy and root resection have been successfully completed with the useful application of bone and teeth-supported surgical stent.

Conclusions

According to these technical reports, the outcome of this guided surgical approach looks to be promising; it was possible to perform guided apicoectomy and root-end resec-

tion as planned and with GEMS protocol adequate consideration of the recommended guidelines for surgical endodontic treatment. The study conducted found that GEMS allows for more accurate surgical access.

Funding

This study was supported by Cornerstone Specialty Products (Grant no. CSP20210115). Two of the authors (Hamid R. Abedi and Farzad Foroughi) have a professional and financial interest in GEMS having filed patents on it (US 2020/0000549A1, US 2020/0306008A1, US 2021/0022831A1) and a trademark under the name of GEMS (Reg. No. 6486821).

Conflict of Interest

None declared.

References

- 1 Chong BS, Pitt Ford TR, Hudson MB. A prospective clinical study of mineral trioxide aggregate and IRM when used as root-end filling materials in endodontic surgery. *Int Endod J* 2003;36(08): 520–526. Doi: 10.1046/j.1365-2591.2003.00682.x
- 2 Saunders WP. A prospective clinical study of periradicular surgery using mineral trioxide aggregate as a root-end filling. *J Endod* 2008;34(06):660–665. Doi: 10.1016/j.joen.2008.03.002
- 3 Tsesis I, Rosen E, Taschieri S, Telishevsky Strauss Y, Ceresoli V, Del Fabbro M. Outcomes of surgical endodontic treatment performed by a modern technique: an updated meta-analysis of the literature. *J Endod* 2013;39(03):332–339. Doi: 10.1016/j.joen.2012.11.044
- 4 Setzer FC, Shah SB, Kohli MR, Karabucak B, Kim S. Outcome of endodontic surgery: a meta-analysis of the literature—part 1: comparison of traditional root-end surgery and endodontic microsurgery. *J Endod* 2010;36(11):1757–1765. Doi: 10.1016/j.joen.2010.08.007
- 5 Strbac GD, Schnappauf A, Giannis K, Moritz A, Ulm C. Guided modern endodontic surgery: a novel approach for guided osteotomy and root resection. *J Endod* 2017;43(03):496–501. Doi: 10.1016/j.joen.2016.11.001
- 6 Kola MZ, Shah AH, Khalil HS, et al. Surgical templates for dental implant positioning; current knowledge and clinical perspectives. *Niger J Surg* 2015;21(01):1–5. Doi: 10.4103/1117-6806.152720
- 7 Kim S, Kratchman S. Modern endodontic surgery concepts and practice: a review. *J Endod* 2006;32(07):601–623. Doi: 10.1016/j.joen.2005.12.010
- 8 Yu SK, Lee MH, Park BS, Jeon YH, Chung YY, Kim HJ. Topographical relationship of the greater palatine artery and the palatal spine. Significance for periodontal surgery. *J Clin Periodontol* 2014;41(09):908–913. Doi: 10.1111/jcpe.12288
- 9 Wang X, Chen K, Wang S, Tiwari SK, Ye L, Peng L. Relationship between the mental foramen, mandibular canal, and the surgical access line of the mandibular posterior teeth: a cone-beam computed tomographic analysis. *J Endod* 2017;43(08):1262–1266. Doi: 10.1016/j.joen.2017.03.043
- 10 Pinsky HM, Champlébox G, Sarment DP. Periapical surgery using CAD/CAM guidance: preclinical results. *J Endod* 2007;33(02): 148–151. Doi: 10.1016/j.joen.2006.10.005
- 11 Giacomino CM, Ray JJ, Wealleans JA. Targeted endodontic microsurgery: a novel approach to anatomically challenging scenarios using 3-dimensional-printed guides and trephine burs—a report of 3 cases. *J Endod* 2018;44(04):671–677. Doi: 10.1016/j.joen.2017.12.019
- 12 Stansbury JW, Idacavage MJ. 3D printing with polymers: challenges among expanding options and opportunities. *Dent Mater* 2016;32(01):54–64. Doi: 10.1016/j.dental.2015.09.018
- 13 Krastl G, Zehnder MS, Connert T, Weiger R, Kühl S. Guided endodontics: a novel treatment approach for teeth with pulp canal calcification and apical pathology. *Dent Traumatol* 2016;32(03):240–246. Doi: 10.1111/edt.12235
- 14 Zehnder MS, Connert T, Weiger R, Krastl G, Kühl S. Guided endodontics: accuracy of a novel method for guided access cavity preparation and root canal location. *Int Endod J* 2016;49(10): 966–972. Doi: 10.1111/iej.12544
- 15 von Arx T, Hänni S, Jensen SSVONARX T. Correlation of bone defect dimensions with healing outcome one year after apical surgery. *J Endod* 2007;33(09):1044–1048. Doi: 10.1016/j.joen.2007.06.010
- 16 Song M, Kim SG, Shin SJ, Kim HC, Kim E. The influence of bone tissue deficiency on the outcome of endodontic microsurgery: a prospective study. *J Endod* 2013;39(11):1341–1345. Doi: 10.1016/j.joen.2013.06.036
- 17 Sisk AL, Hammer WB, Shelton DW, Joy ED Jr. Complications following removal of impacted third molars: the role of the experience of the surgeon. *J Oral Maxillofac Surg* 1986;44(11): 855–859. Doi: 10.1016/0278-2391(86)90221-1
- 18 Kühl S, Payer M, Zitzmann NU, Lambrecht JT, Filippi A. Technical accuracy of printed surgical templates for guided implant surgery with the coDiagnostiX™ software. *Clin Implant Dent Relat Res* 2015;17(Suppl 1):e177–e182. Doi: 10.1111/cid.12152